

HISTO-LOGIC^{T.M.}

Lee G. Luna, D. Lit., H.T. (ASCP), Editor

A Technical Bulletin for Histotechnology

Vol. I No. 1 - July, 1971

HISTO-LOGIC is a publication devoted exclusively to the dissemination of information pertinent to the field of histotechnology. We are fortunate indeed that Lee G. Luna has agreed to edit this new publication. His background, experience, and deep dedication to the profession — and its problems — will bring to the reader a great deal of useful, relevant material.

Since histotechnology is a relatively new art and science, it is felt that there are many messages to be delivered, many mutual problems to be discussed, and in general, a need to establish standards for the profession through a communications "clearing house."

Hopefully HISTO-LOGIC can serve, at least in part, to help fill this void by providing a continuing professional histology-oriented newsletter.

Charles J. Kalt
President, Lab-Tek Products
Div. Miles Laboratories, Inc.

Letter of Intent

The birth of histologic technique dates back to 1664 when Robert Hooke cut sections of cork with his pen knife and observed them microscopically. In 1670, Leeuwenhoek made sections from a writing feather, a bovine optic nerve, and the centers of dried flowers by using his hand-sharpened shaving razor. These historic events were the beginning of what has become, in recent years, an exciting laboratory discipline. Many historical developments could be mentioned; let it suffice to say that the greatest advances in this laboratory field have been made in the 20th Century and particularly during the last two decades. Among the notables of this period were Doctors Frank Mallory, George Gomori and R. D. Lillie. In addition to microscopic investigations of pathological conditions, these dedicated individuals also conducted experiments in histological procedures and staining technologies. Although many accomplishments are evident as the result of the tremendous work conducted by these individuals, there has never been an established system of intercommunication within the field of histological technique.

Two important steps forward in the dissemination of information in the field of histopathology took place in 1965 and 1966. In 1965 a seminar on histopathological technique was sponsored by the North Florida Pathologist Association. This significant program was conceived and promoted by Mrs. Barbara Spillan, Chief Histopathology Technician at the U.S. Naval Hospital, Jacksonville, Florida. To my knowledge this was the first seminar ever presented in this country devoted exclusively to this particular laboratory discipline. In the fall of 1966 the Armed Forces Institute of Pathology conducted its first "Symposium on Histopathologic Technique." This symposium has become an annual event and is designed to: (1) Disseminate information of new technical developments; (2) Stimulate interest for the establishment of seminars, symposiums and/or workshops in various sections of the country; (3) Make histotechnologists aware of the many interesting and stimulating opportunities available in their field. These goals

have been achieved beyond expectation. However, the means of reaching all histotechnologists for a more thorough exchange of information is still deficient.

To a great extent HISTO-LOGIC Newsletter will fulfill this gap. It will also serve the needs of those individuals who are unable to attend the more than 15 seminars, workshops and symposiums conducted annually in this country.

The purpose of this newsletter is:

1. **Interchange of Technical Information.** To be successful we need your contribution of technical information of a practical nature.

2. **Establishment of Tissue Control Centers.** To successfully accomplish this, it is hoped that hospital laboratories will make known when ample control material is available for dissemination to other laboratories.

3. **Technical Inquiry and Reply Service.** Questions concerning histopathologic methodology and procedures are welcomed. Replies will be published. Those inquiries which cannot be answered readily will also be published in order to obtain reader's opinions and conclusions.

4. **Announce Meetings Related to Histotechnology.** Salient information regarding meetings will be published. Requirements for such an announcement will be nature of the meeting, society, location, date and any additional pertinent information.

5. **Provide Information.** Information the editor feels will enhance the knowledge of the histotechnologist and the field of histopathology will be published.

The success or failure of this newsletter is dependent upon the cooperation of all technicians and technologists. Your help is solicited by subscribing, but more importantly by contributing your technical suggestions, modifications and/or developments.

Lee G. Luna, D. Lit., H.T. (ASCP), Editor



Method for Destaining Aldehyde Fuchsin

Aldehyde fuchsin is used for demonstration of elastic fibers, Paget cells, mucosaccharides, pancreatic cells, etc. Because of its wide use it is desirable to have a simple method of removal from previously stained tissue sections on which one desires to perform a different stain.

Potassium Permanganate Solution

Potassium permanganate	0.25 gm
Distilled water	100.00 ml

Sodium Bisulfite Solution

Sodium bisulfite	5.0 gm
Distilled water	100.0 ml

Procedure

1. Deparaffinize and hydrate to distilled water.
2. Place in potassium permanganate solution for 1 minute.
3. Rinse in distilled water.
4. Place in sodium bisulfite solution until section is clear (usually several minutes).
5. Wash in running tap water for 5 minutes.
6. Stain as desired.

Zenker's Fixation and Related Problems

Zenker's fixative has been used for many years for bone marrow, surgical and biopsy specimens. Its primary value lies in its chemical effect on tissue which results in better preservation and differentiation of cell and cell particles. This is due in part to the chemical action of the following ingredients on specific cell structures:

Mercuric chloride, facilitates staining with most dyes, making the colors more brilliant.

Potassium dichromate, fixes cytoplasm without precipitation, producing a homogeneous cytoplasm which reacts well with eosin-type dyes.

Acetic acid, gives life-like preservation to nuclei, penetrates rapidly and swells cell constituents making them more visible microscopically.

These results are only possible if fixation time is controlled. This is best controlled if one understands a hypothesis developed regarding tissue changes during fixation: Tissues undergo three distinct changes during Zenker's fixation. During the first stage, nuclei shrink considerably. Microscopically the nuclear chromatin appears as one dense mass. This normally takes place during the first 2 to 3 hours. This is followed by swelling of the nuclei to approximately their original shape and size. Microscopically the nuclear particles are very distinct as are all cell products. This desirable effect takes place after the first three hours. The third change relates to staining qualities, particularly hematoxylin and eosin preparations. Tissues overexposed to Zenker's fixative will not exhibit the usual hematoxylin staining characteristics. Overexposure (8 hours or longer) produces an acidic staining appearance. Chromatin material cannot be differentiated chromatically and in general nuclei are not distinct. Staining qualities can be restored by placing the deparaffinized slides in a 10% aqueous solution of sodium bicarbonate overnight, followed by routine hematoxylin and eosin staining. Additional problems related to Zenker's fixative are listed below.

Mercuric Chloride Crystals

Mercuric chloride is an ingredient of Zenker's fixative and deposits in tissue as so-called "Zenker crystals." In the classic form, these crystals are spheroid with an irregular periphery. The crystals have also been observed in needle forms and are often polymorphic. Because of the deposition of uncharacteristic forms, they can be confused with other crystalline material. The following method will differentiate mercuric chloride (Zenker) from other crystals which may be present in tissue.

Staining Method for Mercuric Chloride Crystals

20% Ammonium Hydroxide Solution

Ammonium hydroxide, 28% 20.0 ml
Distilled water 80.0 ml

0.2% Light Green Solution

Light green, SF yellowish 0.2 gm
Distilled water 100.0 ml
(Add several crystals of thymol as a preservative.)

Staining Procedure

1. Deparaffinize and hydrate to distilled water.
2. Twenty percent (20%) ammonium hydroxide solution for 30 seconds.
3. Rinse in distilled water (5 dips).
4. Counterstain in light green solution for 30 seconds.
5. Dehydrate in two changes of 95% alcohol, absolute alcohol, and clear in xylene.
6. Coverslip.

Results

Mercuric chloride (Zenker) crystals Black
Background Light green

Remarks

The mercuric chloride crystal color reaction will fade after several weeks. Sections cannot be retreated with the ammonium hydroxide solution if the original reaction is light.

Basic information concerning the reaction was obtained from: Nebergall, W. H. and Schmidt, F. C.: "General Chemistry," D. C. Heath and Company, Boston, Massachusetts, 580, 1959.

Erythrocytic Crystallization

Zenker's fixative will often crystallize erythrocytes. Microscopically the RBC's will exhibit a transparent or a light translucent appearance and possess excellent polarization properties.

Mucosaccharide Alteration

Buffered neutral formalin does not produce any gross alterations affecting the staining properties of hyaluronic acid. Zenker's fixative has an adverse effect on hyaluronic acid and cannot be demonstrated by staining with colloidal iron type preparations. It is not known if other mucosubstances are similarly affected.

Nucleoli Chromatic Alteration

Frequently, nucleoli stain blue after Zenker's fixation. This is in contrast to other fixatives where nucleoli normally stain red after well differentiated hematoxylin and eosin staining.

These remarks are not intended to suggest that Zenker is a poor fixative. But the above information should, if applied, prevent many existing problems related to Zenker's fixation.

Restoration of Nuclear Basophilic Properties

One of the most important aspects of histologic technique is proper staining. Properly fixed, washed, decalcified, and processed specimens pose no staining problems. Frequently, however, one encounters specimens overexposed to unbuffered formalin, Zenker's, Bouin's and/or a decalcifying fluid which subsequently prevents nuclei from staining adequately. In these instances, one of the following methods can be employed to restore the nuclear staining properties of most specimens:

Zenker's Fixative

1. Place deparaffinized sections into 10% aqueous sodium bicarbonate for 6 to 8 hours.
2. Wash slides in running water for 10 minutes.
3. Stain with hematoxylin and eosin.

Unbuffered Formalin and/or Decalcification

For specimens overexposed to unbuffered formalin and/or decalcifying agents, the following method has proven the most useful.

1. Stain deparaffinized sections in Weigert's hematoxylin for 30 minutes.
2. Rinse sections in running tap water.

NOTE: If staining results are too dark, decolorize in 1% acid alcohol (1 ml HCL, 99 ml 80% alcohol). Wash slides in running tap water for 15 minutes.

3. Counterstain with eosin.
- Understand that some overly decalcified bone specimens will not stain regardless of the restoration method used.

Weigert's Iron Hematoxylin Solutions

Solution A

Hematoxylin crystals1.0 gm
Alcohol, 95%q.s. to 100.0 ml

Solution B

Ferric chloride, 29% aqueous4.0 ml
Distilled water95.0 ml
Hydrochloric acid, concentrated1.0 ml

Working Solution

Mix equal parts of Solution A and B and stir vigorously.

Bouin's Fixative

1. Place slides in 5% aqueous lithium carbonate solution for 16 hours.
2. Wash for 30 minutes in running tap water.
3. Stain with hematoxylin and eosin.

The best remedy is prevention. Poor nuclear staining properties can be avoided by prompt removal of specimens from the fixative and/or decalcifying fluid soon after complete fixation or decalcification has been achieved.



A Modified One Hour Giemsa

Elbert Gaffney, Washington, D.C.

The following modification has proven to be a simple, consistent, and reproducible stain for all types of tissue. The staining results are good and seldom vary regardless of the tissue being stained or the technician performing the procedure.

Fixation

Zenker's solution or 10% buffered neutral formalin.

Solutions

Azure II Eosin Solution

Place a few sterile glass beads in a 500 ml amber bottle.

Azure II eosin (Harleco)1.3 gm
Glycerin80.0 ml

Incubate at 56°-60° for 2 hours. Mix and cool.

Add: Methanol170.0 ml
Acetone170.0 ml

May-Greenwald Stain Solution

Combine in one liter Erlenmeyer flask,

May-Greenwald stain (Harleco)0.15 gm
Methanol290.00 ml
Acetone290.00 ml

Combine Azure II eosin and May-Greenwald solutions. This stock solution can be used immediately but improves with aging.

Acetic Water Solution

Glacial acetic acid0.01 ml
Distilled water1000.00 ml

Working Giemsa Solution

Giemsa solution (stock)10.0 ml
Acetic water50.0 ml

Staining Procedure

1. Deparaffinize and hydrate to distilled water.
2. If Zenker fixed, remove mercuric chloride crystals with iodine and sodium thiosulfate (Hypo) in the usual manner.
3. Stain in Giemsa working solution for one hour.
4. Dehydrate in absolute alcohol, three changes.
5. Clear in xylene, three changes.
6. Coverslip.

Results

NucleiBlue
ErythrocytesRed
Mast cell granulesPurple
CytoplasmPink



Substitutes for Ethyl Alcohol in Histologic Techniques

Thomas C. Allen, B.S., Washington, D.C.

A study was conducted to determine where methanol and isopropyl may be used as substitutes for ethyl alcohol in histological techniques.

Specimens of skin and liver were obtained from an autopsy (human) and macrosectioned into blocks approximately 4 millimeters thick.

Fixation

To determine the comparative effects of isopropyl, methanol and ethyl on fresh tissue, specimens were placed in the following for 48 hours. (Also provided are the overall section results.)

1. 10% buffered neutral formalin — Good sections produced.
2. Isopropyl alcohol — Severe shrinkage, especially on the peripheral margins of the tissue.
3. Ethyl alcohol — Moderate shrinkage.
4. Methanol — Slight shrinkage.
5. Formol-alcohol — Good sections produced.

40% formalin10 ml
Alcohol90 ml
Glacial acetic acid5 ml

Comment

Isopropyl and ethyl alcohol should not be used for routine fixation of tissue specimens. Methanol should be used when the preservation of glycogen is desired. Formol-alcohol can be used to expedite fixation especially of biopsy and surgical type tissue specimens.

Tissue Processing

No noticeable tissue differences could be detected among the three alcohols. On the basis of this, isopropyl alcohol and methanol can be used in place of ethyl for tissue dehydration when either xylene or chloroform is used as a clearing agent.

Special Stains

Isopropyl alcohol and methanol were used in the following special stains in the steps calling for ethyl alcohol: Fontana-Masson, Manuel's method for reticulum, Mallory's iron, Masson's trichrome, and periodic acid Schiff.

No significant adverse effects were noted in the above stains except in the Masson trichrome. The aniline blue and biebrich scarlet-acid fuchsin demonstrated collagen and muscle rather light, and therefore methanol and isopropyl should not be used for this technique.

This brief study proved that it is possible to utilize isopropyl alcohol and methanol as substitutes for ethyl in many procedures.


Additional methods and procedures should be attempted.


CHICAGO, ILLINOIS
 PERMIT NO. 4954
 PAID
 U.S. POSTAGE
 BULK RATE


Address Correction Requested
 Division Miles Laboratories, Inc.
 39 East Burlington, Westmont, Illinois 60559
Lab-Tek Products

There could be money in store for you!

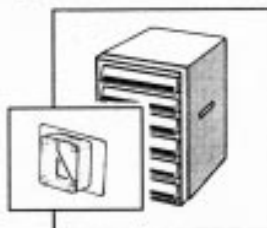
to find out, take this simple test:

1.  Do you use TISSUE-TEK® Embedding Rings?

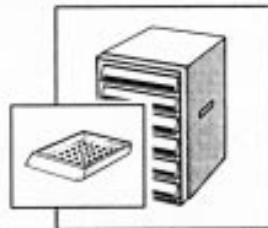
2.  Do you use TISSUE-TEK® Process/Embedding Cassettes?

3.  If you answered "yes" to one of the above questions, then there's money in store for you! You can save from over 10% to 20% just by ordering Lab-Tek's "cabinet complete" (our thrifty little package that consists of one cabinet, and your choice of tissue-tek Rings or tissue-tek Cassettes).

*If you answered #1 & #2 with a "no," skip #3 for now and write us for a free sample of tissue-tek Rings or tissue-tek Cassettes.



TISSUE-TEK Cabinet Complete: Cabinet and Rings. Six plastic drawers with labels to record contents and built-in dividers to accommodate 750 to 1,000 TISSUE-TEK Embedding Rings. Comes with 1,000 Rings. † No. 4169



TISSUE-TEK-III Cabinet Complete: Cabinet and Cassettes. Same cabinet as one at far left, featuring new sturdy dustproof design, and attractive two-tone treatment with identification areas. Holds 1,500 TISSUE-TEK III embedded blocks. Includes 1,500 Cassettes. † No. 4190

†Cabinets also available without Rings or Cassettes.

Editor's Corner

7th Annual Symposium on Histopathologic Techniques 4-8 October 1971

Armed Forces Institute of Pathology, Washington, D.C.

	Morning	Afternoon	Evening
Mon., 4 Oct.	Special Stains Workshop		-----
Tues., 5 Oct.	Tissue Identification Workshop		Exhibits 7-9 P.M.
Wed., 6 Oct.	Lectures/Exhibits	Lectures	Cryotomy & Microtomy
Thurs., 7 Oct.	Lectures/Exhibits	Optional	Cocktails & Banquet
Fri., 8 Oct.	Lectures	Lectures	-----

All activities will be held at the Sheraton Motor Inn, Silver Spring, Maryland.

For information write: Director, Armed Forces Institute of Pathology, Wash., D.C. 20305 ATTN: Lee G. Luna, Rm. 254.

ASCP Conducts "Good Histology Workshop"

The American Society of Clinical Pathologists will present a "Good Histology Workshop," 28 October 1971. The workshop will be in two 3½ hour sessions and will cover histochemistry, stain technology, and related histopathological procedures.

For information write: American Society of Clinical Pathologists, 1300 West Harrison St., Chicago, Illinois 60612.

California Histopathology Technologists' Installation Banquet

The California Society of Histopathology Technologists' Installation Banquet will be held 23 July 1971. The banquet speaker will be Mr. Lee G. Luna, Chief, Histopathology Laboratories, Armed Forces Institute of Pathology, Washington, D.C. For information write: Miss G. Wilma Cline, President, C.S.H.T., 227 DeAnza, San Gabriel, California 91776.

The editor wishes to solicit information, questions, and articles relating to histotechnology. Submit these to: Lee G. Luna, Editor, Histo-Logic, Box 552, Hyattsville, Maryland 20782. Articles, photographs, etc., will not be returned unless requested in writing when they are submitted.

To receive your own personal copy of HISTO-LOGIC, or to have an associate added to the mailing list, write: Lab-Tek Products, Division Miles Laboratories, Inc., 39 E. Burlington, Westmont, Illinois 60559.