

# HISTO-LOGIC<sup>®</sup>

No reader should utilize materials and/or undertake procedures discussed in HISTO-LOGIC articles unless the reader, by reason of education, training and experience, has a complete understanding of the chemical and physical properties of all materials to be utilized and the factors of each material by which any procedure is accomplished.

Editor, Lee G. Luna, D. Lit., H.T. (ASCP)

Technical Bulletin for Histotechnology  
Published: January, April, July, October

Vol. XII, No. 1 - January, 1982

## AUTHOR INDEX ... Vol. XI, 1981

Alexander, M.	157
Bird, T.	169
Boima, R.	166
Bukse, M.	167
Chang, G.W.	165
Chorakian, C.	159
Cordero, V.	169
Dann, G.	167
Dotson, W.	163
Duda, J.J.	161
Duncan, S.	160
Esposito, A.	165
Gerrits, P.O.	165
Goodwin, J.R.	155
Gregory, P.A.	165
Luna, L.G. (Editor)	159, 163
Lundy, J. & Moore, R.	163
Maynard, J.	167
Noble, L.	155
Noble, L. & Challa, V.	164
Payne, C.G.	168
Prust, M.D.	161
Ziaja, J., Granat, V., & Groebbel, E.	159

## SUBJECT INDEX ... VOL. XI, 1981

<b>ARTIFACTS</b>	
An atlas of tissue artifacts	166
<b>HISTOTECHNOLOGY</b>	
Making a desk-top out of a drawer	163
Negative controls - useful idea	157
Other gems for histotechnology	157
Professional or stone age histotech?	159
A word of caution	169
<b>PROCESSING</b>	
Carbol-xylene (a useful tool)	163
Impregnation techniques in the preparation of frozen sections from formalin-fixed tissue	155
Liquid coverslipping media	167
Muscle quenching with liquid nitrogen and talcum powder	164
Quick and easy slide albumizing	169
<b>SECTIONING</b>	
Section adhesive for paraffin sections	165
Strict serial sectioning with particular reference to bone and dense fibrous tissue	155
<b>STAINS, STAINING, STAIN TECHNOLOGY</b>	
Hematoxylin-eosin/phaoxine stain	167
Liver trichrome stain	163
Methyl green pyronin	169
Microtomy and staining of cataract lens	160
A modification of Southgate's nuclear fast blue method	168
A modified aldehyde thionin method for demonstrating hepatitis B surface antigen (HBsAg)	159
Problems related to staining of connective tissue embedded in water-soluble plastics	165

## "B" is for Boston

Start making plans now to join us for the 8th Annual Symposium/Convention of the National Society for Histotechnology. We'll convene at the Sheraton Boston for five exciting days of learning, exchange of ideas, scientific sessions and workshops. Look for a complete schedule of activities in future issues of Histo-Logic. Mark your calendar today!

NSH SYMPOSIUM/CONVENTION  
September 13-17, 1982  
BOSTON, MASSACHUSETTS



## Volume Surface Ratios in Tissue Fixation

Paul R. Monfils  
Rhode Island Hospital  
Providence, Rhode Island 02902

Cell physiologists have long been aware of the critical role of volume/surface ratios in regulating cell growth. Since the water, oxygen and nutrients utilized in cell metabolism must enter through the cell membrane, the ratio of cellular volume to membrane surface area cannot exceed certain predetermined limits. The principle of volume/surface ratio applies similarly during fixation of tissue specimens for histologic examination.

Optimum staining reactions resulting in distinct cellular detail can be achieved only when initial fixation has been sufficiently prompt and rapid to arrest autolysis and microbial growth before irreversible biochemical and morphological changes have occurred. Since fixation of the entire tissue volume depends on diffusion of chemical fixative into the tissue through its outer surface, the ratio of unfixed tissue volume to available surface area is an important consideration. In fact, it is far more crucial than the ratio of tissue volume to fixative volume, though the latter principle is more generally understood and observed.

Consider the following example: A prosector dissects two large blocks of tissue from a spleen, and fixes them for future examination. Block A measures 1.0 x 10.0 x 20.0 cm, while Block B measures 5.0 x 5.0 x 8.0 cm. Each tissue sample is placed into a quart of neutral buffered 10% formalin. A week later, the tissue is subdivided, processed and embedded in paraffin. Microscopically, sections from Block A show excellent staining characteristics, with distinct nuclear detail. Surface areas of Block B yield some satisfactory preparations, but sections from the deeper levels reveal advanced autolytic change, with greatly reduced intensity of staining, contraction and fragmentation of nuclear chromatin and appearance of cytoplasmic artifacts.

Since the two blocks of tissue in the above example were identical in weight and volume (200.0 cc each), and were treated with equal volumes of the same fixative for identical time periods, the disparity in results could be a bit puzzling. However, a brief mathematical exercise reveals the source of the problem. The 460 cm<sup>2</sup> surface area of Block A allowed fixative to diffuse in rapidly enough to thoroughly fix 200 cc of tissue within a reasonably short time span, while the 210 cm<sup>2</sup> surface area of Block B proved inadequate. In other words, the relatively high volume/surface ratio of Block B precluded rapid penetration and fixation, while the relatively low volume/surface ratio of Block A favored quick and thorough fixation. It is apparent, therefore, that objects of equal volume will have different volume/surface ratios when their shapes differ.

It is likewise true that objects similar in shape will have higher volume/surface ratios as their size increases. For example, three cubes having sides of 1.0 cm, 2.0 cm and 3.0 cm respectively, will have volumes of 1.0 cc, 8.0 cc and 27.0 cc, and surface areas of 6.0 cm<sup>2</sup>, 24.0 cm<sup>2</sup>, and 54.0 cm<sup>2</sup>. Their respective volume/surface ratios would therefore be 0.16, 0.33 and 0.50. The effect of volume/surface ratio on tissue fixation points to the absolute necessity of trimming tissue samples intended for histologic study as small and as thin as is practical.

Casseted tissue presents additional considerations. The tissue cassettes most commonly used in medical histology laboratories have inside dimensions of 5 x 26 x 32 mm, or a maximum capacity of 4,160 mm<sup>3</sup>. A bottom perforated with thirty-four 2-mm holes, and a similarly perforated metal lid, normally permit an adequate flow of fixative solution around the tissue to bring about rapid and complete fixation. A tissue sample trimmed slightly smaller than the 26 x 32 mm limits of the cassette, and 2 mm thick, has a volume/surface ratio of 0.87, which virtually guarantees perfect fixation. Increasing the thickness to 4 mm raises the volume/surface ratio to 1.54, still low enough to favor thorough fixation in fresh fixative solution. However, when the thickness reaches or exceeds 5 mm, the tissue is pressed against the bottom and lid of the cassette, allowing no fixative circulation between the tissue and the plastic or metal. This reduces the surface area available for fixative penetration to the minute circles of tissue which are pressed against the perforations of the cassette. The effective volume/surface ratio of tissue cassetted in this manner may be well over 15.0, which virtually guarantees that the tissue will not be properly fixed. In fact, the deeper levels of such tissue samples frequently remain totally unfixed, and are consequently useless for diagnostic purposes.

Tissue fixation is a "now or never" operation. Tissue samples which are not properly fixed as soon as possible after excision may be reprocessed later, but no amount of secondary fixation or reprocessing can reverse cellular damage produced by lack of proper initial fixation. Members of the pathology team responsible for initial prosection of surgical specimens must be aware of the general principles of tissue fixation if histology personnel are expected to produce microscopic preparations of prime quality. Tissues which are too soft to cut thin in the fresh state should be briefly prefixed and hardened prior to prosection whenever possible. The use of injector-type razor blades will often provide clean, thin sections of tissues which crush under a scalpel blade. Tissue samples which must be cut too large for a standard cassette should not be placed into a standard cassette. They may be easily processed without a cassette, or larger cassettes should be provided. Stainless steel "tea eggs" or metal 35-mm film canisters (with ample perforations having been provided by the technician) serve nicely in this capacity. (Film canisters are usually aluminum, and are not recommended for use in acid solutions.)

In histotechnology, a gram of prevention is worth a

kilogram of cure. Disease diagnosis is a team effort, and support and cooperation among the various elements of the team will ensure maximum quality, minimum delay and optimum all-around efficiency, to the benefit of technician, pathologist and patient.

## Proper Tissue Placement During Embedding Procedure

Mequita D. Praet  
Susie Parker Stringfellow Memorial Hospital  
Anniston, Alabama 36203

Very often while trying to teach a student how to embed different types of tissues, the need arose for visual aids which the student could study before beginning the embedding process. Due to the lack of any actual reference\* material on embedding tissue, my pathologist, Dr. Carl W. Nichols, and I drew the following pictures which hopefully will be of some aid to those experiencing the same dilemma.

\*Editorial Comment: The following reference provides additional information on embedding different types of tissue: Anzman, T.R.: Blocking procedure in histopathological technique. *Amer. J. Med. Tech.*, 33(2): 129-133, 1967.

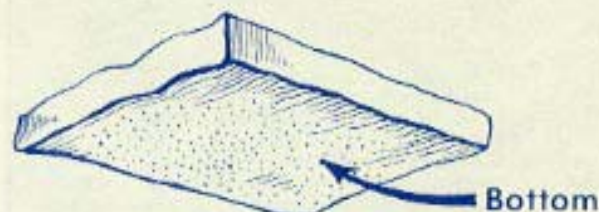

Figure 1:  
Flat tissue section — Embed on flat cut surface.  
Examples: Ovary, breast tissue, lymph node, uterine sections (cervix and uterine body), tonsils, placenta, lipoma, thyroid, keloids, tip of appendix.

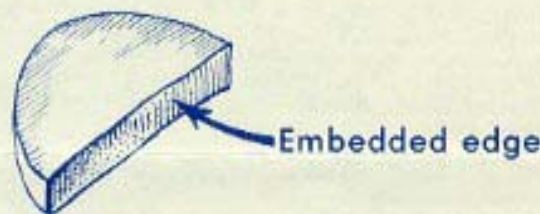


Figure 2:  
Cut surface — Embed on cut surface of tissue section.  
Examples: Bisected skin ellipses, hemorrhoids.


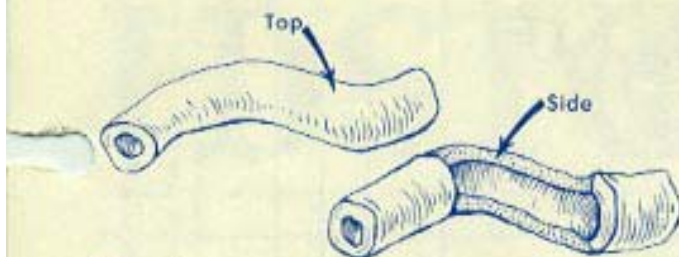
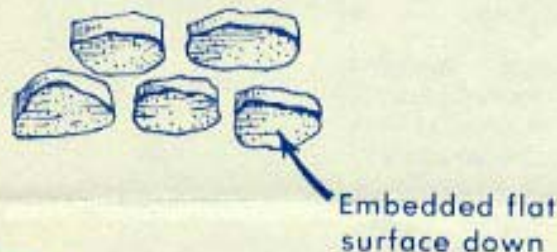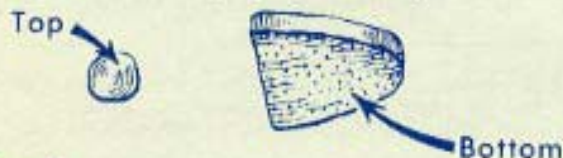


Figure 3:  
Segmental section — Embed on flat surface of segment.  
Examples: Tubular tissues with a lumen, such as fallopian tubes, vas deferens, varicose veins, appendix, umbilical cord.



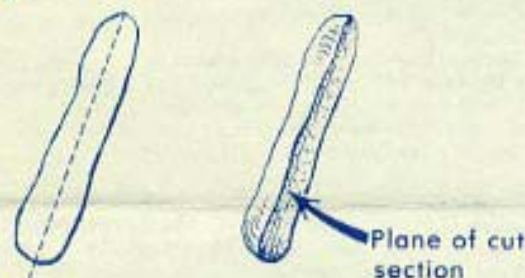
**Figure 4:**  
Section of tissue with large lumen — Embed on cut surface to demonstrate lining.  
*Examples:* Intestine, foreskin, hernia sac, ganglion cyst, gallbladder, pterygia.



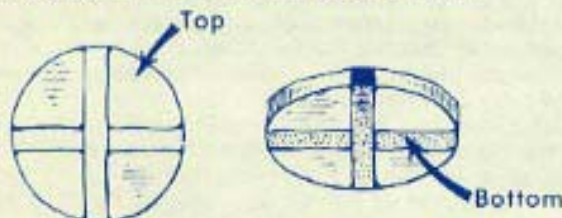
**Figure 5:**  
Curettage biopsy — Embed fragment longitudinally to see as much of tissue as possible.  
*Examples:* Uterine scrapings, prostate chips.



**Figure 6:**  
Circular or horseshoe shaped punch biopsy — Embed on end to show horseshoe shape.  
*Examples:* Cervical biopsy, bladder biopsy, biopsy of GI tract.



**Figure 7:**  
Larger polypoid lesions — Embed on long axis to show plane of cut section.  
*Examples:* GI and endometrial polypoid lesion.



**Figure 8:**  
Resection with surgical margins indicated by India ink — Embed on side with India ink on medial or lateral extremes.  
*Examples:* Skin excisions for carcinoma or melanoma.

## Hints on Cleaner Histologic Slides

Carol Eriele  
Kidney Disease Institute  
Albany, New York 12201

In response to the editorial on debris deposited on tissue sections which appeared in *Histo-Logic*, Vol. IX, No. 1, January 1979, the following is provided.

Assuming slides, solutions, and stain are clean — was there more than one section on that particular slide? If so, examine the same field on the duplicate tissue section. If the debris appears on all sections, it may be in the embedding wax. Filter your wax.

I have a pet peeve about dust particles settling on the flotation bath. These particles are picked up on the tissue section and the slide is then dried in the incubator. This heat treatment may explain the strong bond between floating debris and the tissue section or glass slide.

To prevent flotation bath debris, I use a very thin sheet of 10 x 10 tissue paper (hand towels, Kleenex, etc.), place paper over entire water surface, then sweep paper over bath. This assures a clean, dust-free surface after the removal of each group of sections. This also cuts down on "pick-ups" from the preceding specimen, avoiding embarrassing situations for the technician and the pathologist.

One other form of debris is by writing on frosted end slides with lead pencils. The lead from the pencil tends to dislodge from the frosted end and settles on the tissue section, and is then observed on the tissue microscopically.

## Filing System for Chemicals

Susan Schultz\*  
Baptist Medical Center  
Little Rock, Arkansas 72201

As a new student in the field of histotechnology, I had expected to find learning the many special stains frustrating. One thing I did not anticipate being so baffling was having to pinpoint the location of each chemical I had to use, to compound solutions and stains. For example, it required digging my way through a sea of bottles to find one bottle of oxalic acid. At this point in my training, I had just been exposed to some of the long chemical terms; now I had to search them out! It became apparent that something had to be done about that unorganized maze of bottles.

A whole new system of labelling was devised, which involved assigning each bottle a number. The number 14 just seemed easier to find than the term phosphotungstic acid hematoxylin (especially to an unfamiliar eye). White adhesive tape was used and the numbers written in black with a magic marker. The labels were affixed to the top and side of the jars for easy recognition from any angle.

Some type of order was needed for the numbering system. This was accomplished by making the numerical order coincide with the alphabetical order of the chemical names. A list of the chemicals with their newly assigned numbers was then typed and taped to the inside door of the cabinets where the chemicals were kept.

This new system of organization has added much to the efficiency of special staining techniques in our laboratory.

\*Ms. Schultz was a student of histotechnology when this article was submitted for publication in January 1980.

**MOVED? NEW NAME?**

Please print corrections below and return with old label to Lab-Tek. Mailing list updated quarterly. Allow 90 days for address corrections.

Name \_\_\_\_\_

New Address \_\_\_\_\_

City/State \_\_\_\_\_ Zip \_\_\_\_\_



LAB-TEK DIVISION  
Miles Laboratories, Inc.  
30W475 North Aurora Rd.  
Naperville, IL 60566  
Address Correction Requested

BULK RATE  
U.S. POSTAGE  
PAID  
PERMIT NO. 4954  
Chicago, Illinois

## Write on and on and on . . . Tissue-Tek® III Cassette System™ for accurate, time-saving specimen identification.



Lab-Tek Division **MILES**  
The histology systems source

Tired of transferring specimen I.D. numbers with capsules and rings? Now you can have one-time I.D. from grossing to filing, plus three writing surfaces for your permanent specimen identification.

These cassettes have a high resistance to solvents and decalcifying solutions; and they are compatible with microwave techniques. Unique snap-latch and hinge lock provide positive specimen retention and a disposable lid means no more metal covers to clean. All designed to make your lab life easier . . . from LAB-TEK.

Call your LAB-TEK distributor today about the convenient Tissue Tek III Cassette System which includes:

- Uni-Cassette™
- Uni-Cassette in Four Colors for better organization
- Biopsy Uni-Cassette™ with 1mm pores. Helps eliminate the need to wrap most biopsy-type specimens.
- Mega-Cassette™ for larger specimens such as bone, eyes and teeth. Special Mega-Cassette base mold also available.

## Oil Discovery in Histology

Bonnie Hemplemann  
Phelps County Memorial Hospital  
Rolla, Missouri 65401

While loading a basket of tissue on the Technicon Ultra (with oil bath), red oil was noticed on the first three solutions. The beakers were taken out of the machine and the oil bath checked to see if any of the solutions had drained into the oil; the oil was clean. The beakers were then washed in hot soapy water and dried. I was concerned about using the machine without knowing what had happened or if it would occur again. About this time one of our pathologists held the first beaker up to the light and could see a small stellate crack in the bottom of the beaker. Under normal conditions it wasn't large enough to let any liquid flow through, but when 15 inches of mercury pressure was applied, the oil was pulled in-

to the beaker. It was then carried by the basket of tissue into the succeeding solutions. After replacing the defective beaker there were no further problems.

After thinking about the problem, the realization came to me that when I set the machine on the weekend, I always turned the machine on, which immediately activated the vacuum pump; then I set the time delay. It was assumed the vacuum was lost in a short time, but one of the pathologists noticed the vacuum pressure frequently remained at 15 inches of mercury all weekend. We feel it was this long period of pressure on the first beaker that caused it to crack. I now set the time delay on weekends and then turn the machine on.

Our laboratory uses transmission fluid instead of mineral oil in the Ultra. It does not require changing every six months, does not develop a strong odor and does not facilitate the growth of fungus. The inherent red color of transmission oil brought the problem to my attention much sooner than mineral oil would have.

To receive your own personal copy of HISTO-LOGIC, or to have an associate added to the mailing list, submit home address to: Lab-Tek Division, Miles Laboratories, Inc., 30W475 North Aurora Rd., Naperville, Illinois 60566

Printed in U.S.A.

The editor wishes to solicit information, questions, and articles relating to histotechnology. Submit these to: Lee G. Luna, Editor, Histo-Logic, P.O. Box 36, Lanham, Maryland 20706. Articles, photographs, etc., will not be returned unless requested in writing when they are submitted.